

Thermography Clinic Inc.

Thermal Breast Imaging Report

Patient Name: Smith, Jane
Date of Birth: 02-26-44
Referring Physician: Self
Date of Examination: 11-12-07
Examination: Breast Thermography

Brief Historical Overview: Patient reported with a palpable lump in the right breast at 8-9 o'clock. No other tests or reports available at the time of this evaluation. Strong family history of breast cancer.

Subjective Complaints: Routine screening.

Preface:

Thermography is utilized to view the amount of heat emitted from the skin's surface. This provides a territorial analysis of the surface of the temperature with specific quantitative measurements taken of questionable regions. As a general note, the radiation wave length observed is at the infrared end of the light spectrum. Special instrumentation is required for this examination, noting that infrared rays are invisible to the unaided human eye. The thermograms demonstrate these heat emissions as colors or as black and white images. The colors or shades of black and white will differ in various parts of the body, but in a normal healthy individual, the temperature changes should be relatively symmetrical.

This patient was evaluated with FLIR A-40M Infra Red Camera, with examination guidelines followed, as set forth by the International Academy of Clinical Thermology. Multiple series were performed providing a provocative challenge to aid in the physiological assessment of the breasts.

Explanation of Delta-T Measurements: The breasts are compared right to left in identical locations. The difference in temperature for each area is termed Delta-T (ΔT) and is reported in degrees Celsius. Relative values for rating purposes have been established as follows:

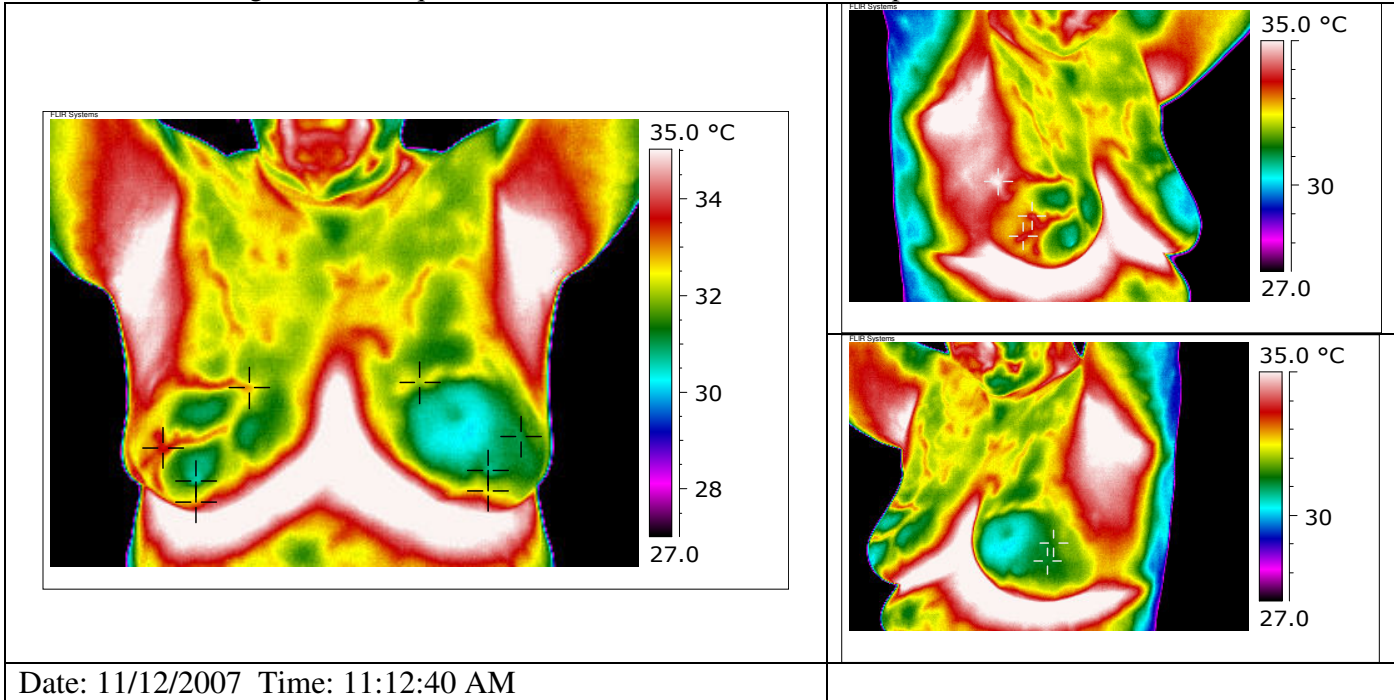
Delta-T	1.0 °C or higher at the nipple
Delta-T	1.5 °C or higher in the periareolar area
Delta-T	2.0 °C or higher in the area of clinical finding
Delta-T	3.0 °C or higher in isolated areas without clinical finding

In the opinion of this evaluator, any delta above 1.0 °C at the nipple or 2.0 °C elsewhere should be clinically correlated by the referring physician and if negative, monitored thermographically for at least one year. These numbers represent only a guideline in the overall risk evaluation of the patient's breasts.

Thermography Clinic Inc.

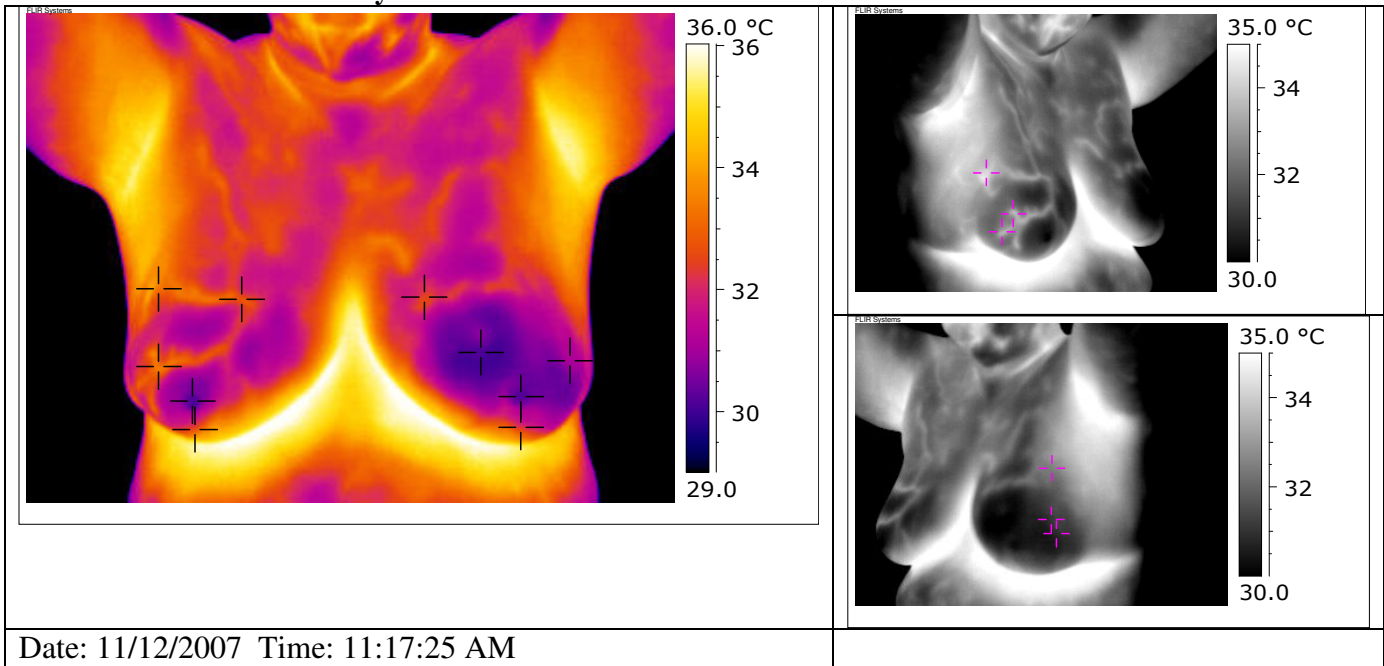
Thermographic Findings: Series One: Baseline Study

Performed following 15 minute equilibration at 21.0 °C ambient room temperature.



Nipple	Right = 30.8 °C	Left = 30.8 °C	$\Delta T = 0.0$ °C
Periareolar	Right = 32.8 °C	Left = 32.4 °C	$\Delta T = 0.5$ °C

Series Two: Functional Study



Nipple	Right = 30.1 °C	Left = 30.1 °C	$\Delta T = 0.0$ °C
Periareolar	Right = 32.9 °C	Left = 32.3 °C	$\Delta T = 0.6$ °C

Series 2 Quantitative analysis of temperature in degree's Celsius compared to baseline images:

Performed 20 minutes post onset of examination and following a 60 second hand soak in 10 °C water. This provides an autonomic challenge and a response of sympathetic vaso-constriction. The skin's microcirculation is further shut down and we are able to contrast any non-responsive blood vessels that may be associated with malignant neoplasms. This includes the neo-angiogenic blood vessels and those that are dilated because of nitric oxide. Ambient room temperature remained at 21.0 °C

Thermography Clinic Inc.

Observational Note: The Delta T between the right and left nipple is less than 1.0°C and remains within normal limits for this study. The Delta T between the right and left periareolar region is lower than 1.5°C which is within normal limits.

Impression:

Right Breast: TH-4, Score = 135

- Curvilinear Thermovascular Pattern Upper Breast Score = 25
- Thermovascular Network Score = 10
- Asymmetrical Thermal Pattern Score = 15
- Regional Hyperthermia lateral aspect at 11 o'clock Score = 20
- Vascular Hyperthermia $\Delta T \geq 2^\circ\text{C}$ (Contralateral) extending from 8 to 10 o'clock Score = 25
- Hyper-vascularization of one breast >25% Score = 40

Left Breast: TH-2, Score = 50

- Curvilinear Thermovascular Pattern Upper Breast Score = 25
- Thermovascular Network Score = 10
- Asymmetrical Thermal Pattern Score = 15

Discussion:

Right Breast TH-4 – Abnormal regarding thermal emission. Numerical values of 120-149, finding is considered high risk and should be followed closely.

Left Breast TH-2 – Within normal limits regarding thermal emission. Numerical values of 30-74, statistically, most frequently associated with benign disorders such as cystic and fibrocystic breasts.

Clinical Comment:

This thermographic evaluation requires physician examination and other structural testing to rule out current pathology and then routine follow-up with thermography as a screening and monitoring procedure for these particular vascular signatures.

Thermography provides a physiological assessment of the microcirculation and is quite sensitive for the detection of risk factors regarding several pathological conditions. This test, however, does not replace or discourage clinical findings or mammography and any suspicious lesions should be followed up with additional testing or medical evaluation.

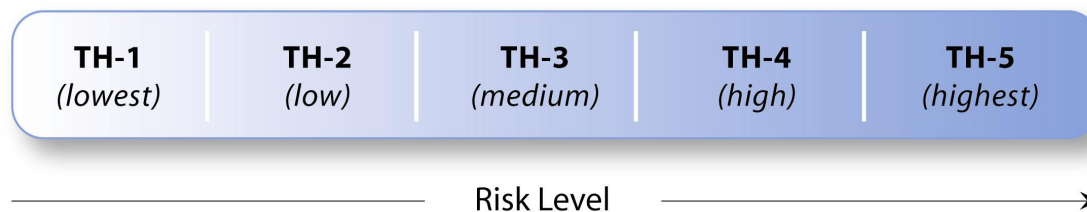Follow-up: The patient should have follow-up thermographic evaluation for comparison to this examination in six months time.

A. Mostovoy, H.D., D.H.M.S., B.C.C.T.
Board Certified Clinical Thermographer

Thermography Clinic Inc.

TH Report System: Standard Qualitative and Quantitative Analysis

The thermographic findings presented in this study were evaluated based on 32 standard thermological signs and quantification changes, during the course of the examination. Each of these were provided with numerical values (scores), which were developed based on the statistical frequency of occurrence and its association with breast pathology. Scores of 0-29 presents relatively symmetrical and avascular patterns and are considered statistical normals. Scores of 30-74, were also considered within normal limits, but usually displayed some thermovascular patterns and statistically appeared to be associated mainly with benign breast distortions. It is noted, that the higher the score appears in this group, the incidence of pathology increases



TH-1 Score	0-29	Within normal limits regarding thermal emission
TH-2 Score	30-74	Within normal limits regarding thermal emission. Most frequently associated with benign disorders such as cystic and fibrocystic breasts.
TH-3 Score	75-119	Equivocal regarding thermal emission. Finding is possibly benign but is considered at risk and should be followed closely.
TH-4 Score	120-149	Abnormal regarding thermal emission. Finding is considered high risk.
TH-5 Score	≥ 150	Abnormal regarding thermal emission. Finding is considered very high risk.

Regarding carcinoma, regardless of tumor size and histological type, the average thermal score was found to be higher than 80. The in situ carcinomas, the microinvasive carcinomas (< 5mm), and T1 Cancer (< 2cm) had average scores of 87, 92 and 129 respectively. (Gautherie)

* TH scoring system is based on original research conducted by M. Gauthrie, A. Kotewicz and P. Gueblez. Study presented in Thermal Assessment of Breast Health, entitled “Accurate and objective evaluation of breast thermograms: basic principles and new advances with special reference to an improved computer-assisted scoring system.” Published by MTP Press Limited, Lancaster/Boston. Since Gautherie’s original research, additional signs and numerical values have been added, to establish the present scoring system (as used for in this report). These additional signs and values are based in extensive imaging and clinical work, separately performed by Dr’s G. Chapman and B. Hobbins.